

PHACO NIGHTMARES

GLUED PC IOL IMPLANTATION WITH INTRALAMELLAR SCLERAL TUCK IN EYES WITH DEFICIENT CAPSULE

AMAR AGARWAL

INTRODUCTION

Posterior capsular rent (PCR) ¹⁻² can occur in early learning curve in phacoemulsification. Intraoperative dialysis or large PCR will prevent intraocular lens (IOL) implantation in the capsular bag. Implantation of IOL in the sulcus will be possible in adequate anterior capsular support. The first glued PC IOL implantation in an eye with a deficient capsule was done by the authors on 14th of December 2007. In eyes with inadequate anterior capsular rim and deficient posterior capsule, the new technique of IOL implantation is the fibrin glue assisted sutureless IOL implantation with scleral tuck. ³⁻⁷

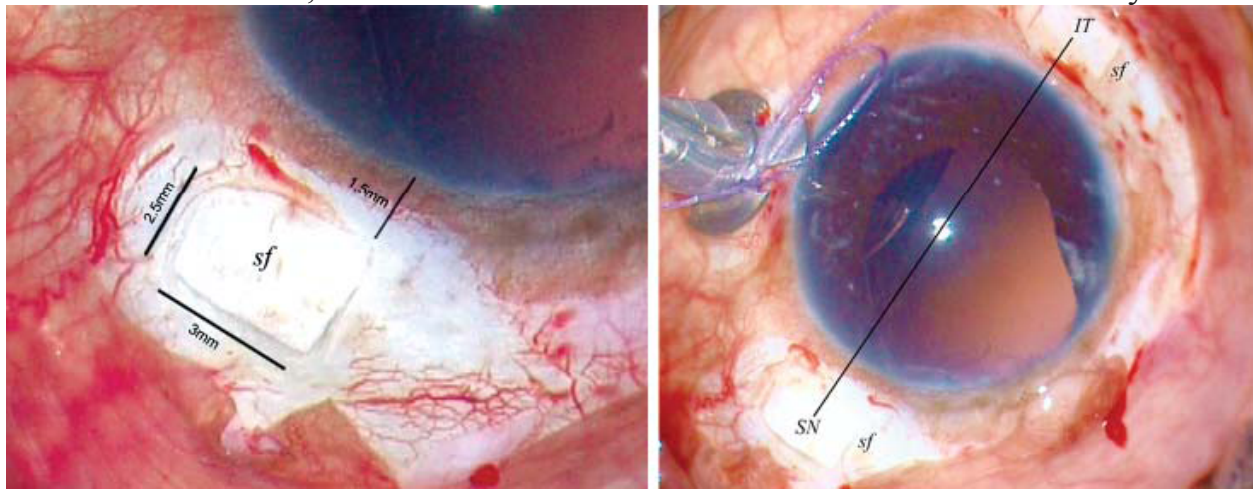
SURGICAL TECHNIQUE

Under peribulbar anesthesia, superior rectus is caught and clamped. Localized peritomy and wet cautery of the sclera at the desired site of exit of the IOL haptics is done. Infusion cannula or anterior chamber maintainer is inserted. If using an infusion cannula, one can use a 23 G sutureless trocar and cannula. Positioning of the infusion cannula should be preferably in inferonasal quadrant to prevent interference in creating the scleral flaps. Two partial thickness limbal based scleral flaps about 2.5 mm × 3 mm are created exactly 180 degrees diagonally apart (**Figures 1A and B**). This is followed by 23 G vitrectomy via pars plana or anterior route to remove all vitreous traction. Two straight sclerotomies with a 20G/22G needle are made about 1.0 mm from the limbus under the existing scleral flaps. A clear corneal/scleral tunnel incision is then prepared for introducing the IOL. While the IOL is being introduced with the one hand of the surgeon using a McPherson forceps, an end gripping 23 G/25 G microrhexis forceps (Micro Surgical Technology, USA) is passed through the inferior sclerotomy with the other hand. One can use any end opening forceps like a micro rhexis forceps. The

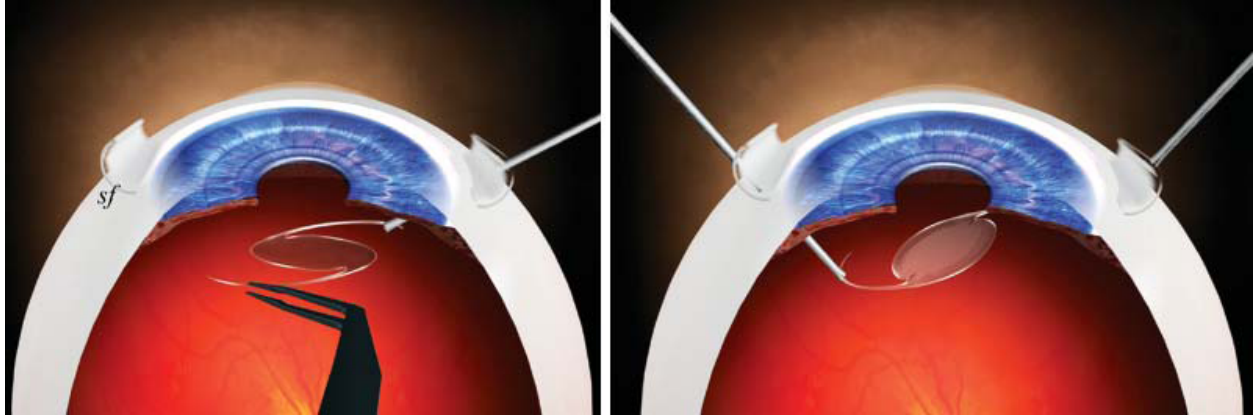
tip of the leading haptic is then grasped with the microrhexis forceps, pulled through the inferior sclerotomy following the curve of the haptic (**Figures 2A and B**) and is externalized under the inferior scleral flap. Similarly, the trailing haptic is also externalized through the superior sclerotomy under the scleral flap. Limbal wound is sutured with 10-0 monofilament nylon if it is a sclera tunnel incision. The tips of the haptics are then tucked inside a scleral tunnel made with 26 G needle at the point of extension. Scleral flaps are closed with fibrin glue (**Figures 3A and B**). The anterior chamber maintainer or the infusion cannula is removed. Conjunctiva is also closed with the same fibrin glue (**Figure 4**)

FIBRIN GLUE

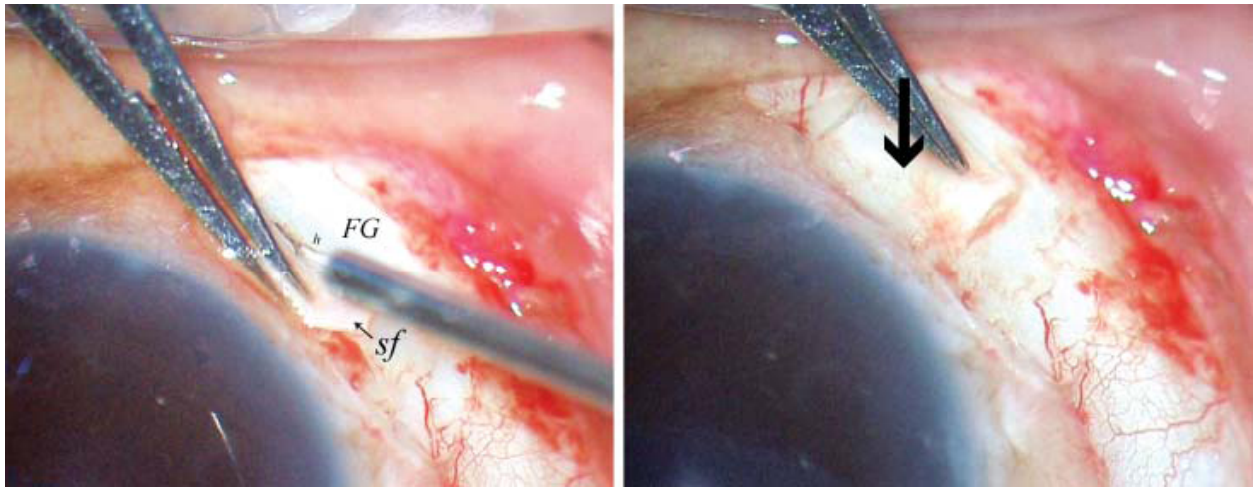
The fibrin kit the author used is Reliseal (Reliance Life Sciences, India). Another widely used tissue glue namely Tisseel (Baxter) can also be used. The fibrinogen and thrombin are first reconstituted according to the manufacturer's instructions. The commercially available fibrin glue that is virus inactivated is checked for viral antigen and antibodies with polymerase chain reaction; hence the chances of transmission of infection are very



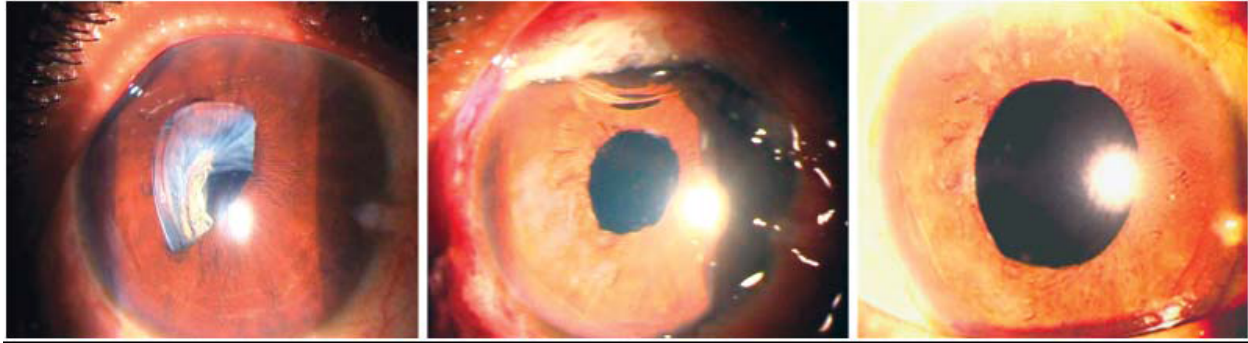
FIGURES 1A and B: Scleral flaps (sf) of 2.5 x 3 mm made about 1.5 mm from the limbus. Two flaps 180 degrees diagonally apart



FIGURES 2A AND B: Image showing sclerotomy made with 22 G needle beneath the flaps Haptics exteriorized by 25 G forceps beneath the scleral flaps (sf)



FIGURES 3A AND B: Reconstituted fibrin glue (FG) injected beneath the scleral flaps over the haptics and scleral flaps (sf) closed



FIGURES 4A TO C: (A): Preoperative slit lamp image showing anterior subluxated IOL, (B) Day one postoperative period, (C) Three months after surgery

low. But with tissue derivatives, there is always a theoretical possibility of transmission of viral infections.

Reconstitution of Reliseal

It is available in a sealed pack, which contains freeze dried human fibrinogen (20 mg/0.5 ml), freeze dried human thrombin (250 IU/0.5 ml), aprotinin solution (1500 kiu in 0.5 ml), one ampoule of sterile water, four 21G needles, two 20 G blunt application needles and an applicator with two mixing chambers and one plunger guide. First, the aprotinin solution is taken in a 2 ml sterile syringe and mixed with the freeze dried fibrinogen and is then shaken by slow circular motion. The reconstituted vial is then placed in a preheated water bath of 37 degrees for not more than 10 minutes. Next, about 0.5 ml of water for injection is aspirated and injected into the vial of freeze dried thrombin followed by gentle agitation of the vial. Reconstitution is considered complete when no undissolved particles are visible. Both the reconstituted fibrinogen and the thrombin are loaded separately in two 2 ml sterile syringes and mounted on to the Reliseal applicator for use.

Then, the reconstituted fibrin glue thus prepared is injected through the cannula of the double syringe delivery system under the superior and inferior scleral flaps. Local pressure is given over the flaps for about 10–20 seconds for the formation of fibrin polypeptides.

Special Situations

In case of those patients who had a luxated IOL, similar lamellar scleral flaps as described earlier are made and the luxated IOL haptic is then grasped with the 23/25 gauge rhexis forceps and externalized and glued under the sclera flaps (**Figures 5A and B**).

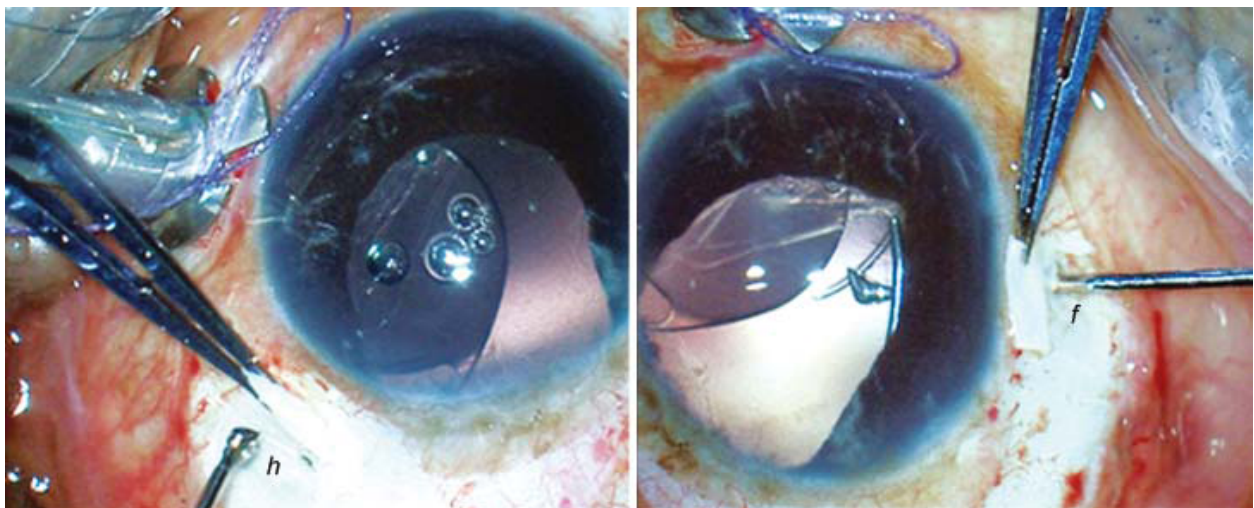
Advantages

This fibrin glue assisted sutureless PCIOL implantation technique would be useful in a myriad of clinical situations where scleral fixated IOLs are indicated, such as luxated IOL, dislocated IOL, zonulopathy or secondary IOL implantation.

No special IOLs: It can be performed well with rigid PMMA IOL, 3 piece PC IOL or IOLs with modified PMMA haptics. One, therefore, does not need to have an entire inventory of special SFIOLs with eyelets, unlike in sutured SFIOLs. In dislocated posterior chamber PMMA IOL, the same IOL can be repositioned, thereby reducing the need for further manipulation. Furthermore, there is no need for newer haptic designs or special instruments other than the 25 gauge forceps.

No tilt: Since the overall diameter of the routine IOL is about 12–13 mm, with the haptic being placed in its normal curved configuration and without any traction, there is no distortion or change in shape of the IOL optic (**Figure 6**). Externalization of the greater part of the haptics along its curvature stabilizes the axial positioning of the IOL and thereby prevents any IOL tilt.⁸

Less pseudophacodonesis: When the eye moves, it acquires kinetic energy from its muscles and attachments and the energy is dissipated to the internal fluids as it stops. Thus,



FIGURES 5A AND B: *Haptics (h) exteriorized by 25G forceps (f) beneath the scleral flaps (sf) in dislocated IOL*

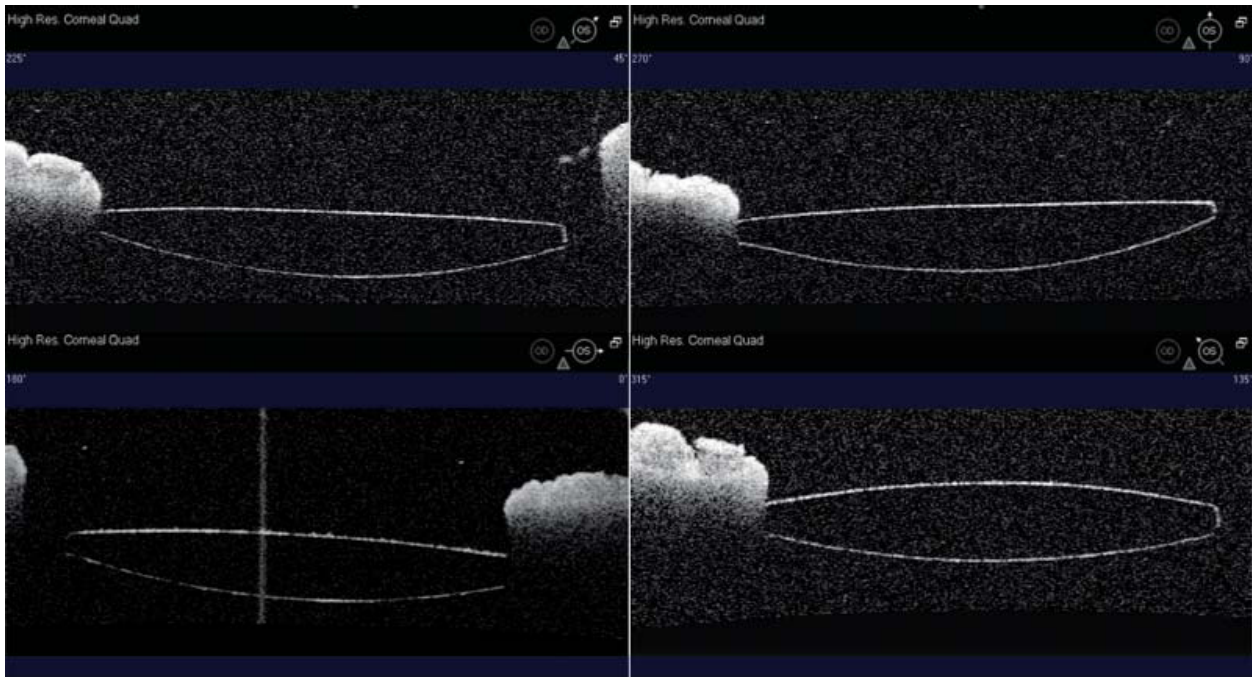


FIGURE 6: *Anterior segment OCT showing 360 degrees good centration of the IOL*

pseudophacodonesis is the result of oscillations of the fluids in the anterior and posterior segment of the eye. These oscillations, initiated by movement of the eye, result in shearing forces on the corneal endothelium as well as vitreous motion lead to permanent damage. Since the IOL haptic is stuck beneath the flap, it would prevent the further movement of the haptic and thereby reducing the pseudophacodonesis.⁹

Less UGH syndrome: The authors expect less incidence of UGH syndrome in fibrin glue assisted IOL implantation, as compared to sutured scleral fixated IOL. This is because; in the former, the IOL is well stabilized and stuck onto the scleral bed and thereby, has decreased intraocular mobility, whereas in the latter, there is increased possibility of IOL movement or persistent rub over the ciliary body.

No suture related complications: Visually significant complications due to late subluxation¹⁰ which has been known to occur in sutured scleral fixated IOL may

also be prevented as sutures are totally avoided in this technique. Another important advantage of this technique is the prevention of suture related complications,^{11,12} like suture erosion, suture knot exposure or dislocation of IOL after suture disintegration or broken suture.

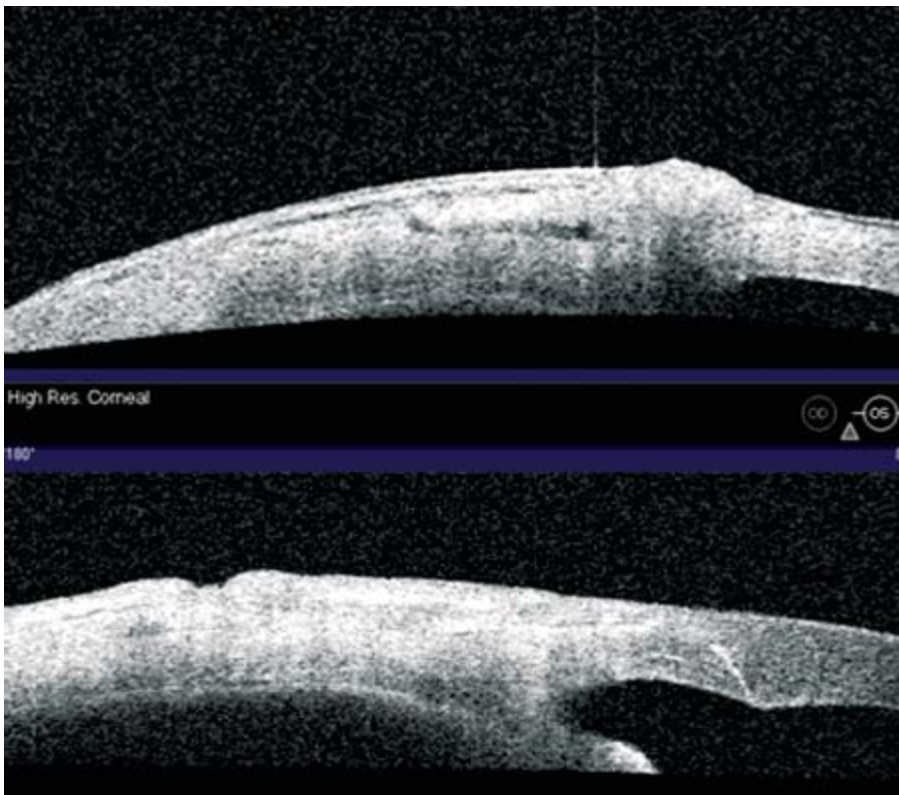
Rapidity and ease of surgery: All the time taken in SFIOL for passing suture into the IOL haptic eyelets, to ensure good centeration before tying down the knots, as well as time for suturing scleral **flaps** and closing conjunctiva are significantly reduced. The risk of retinal photic injury¹³ which is known to occur in SFIOL would also be reduced in this technique due to the short surgical time. Fibrin glue takes less time [Reliseal (20 seconds)/Tisseel (3 seconds)] to act in the scleral bed and it helps in adhesion as well as hemostasis. The preparation time can also be reduced in elective procedures by preparing it prior to surgery as it remains stable up to four hours from the time of reconstitution. Fibrin glue has been shown to provide airtight closure and by the time the fibrin starts degrading, surgical adhesions would have already occurred in the scleral bed. This is well shown in the follow-up anterior segment OCT (**Figure 7**) where postoperative perfect scleral flap adhesion is observed.

Stability of the IOL Haptic


As the flaps are manually created, the rough apposing surfaces of the flap and bed heal rapidly and firmly around the haptic, being helped by the fibrin glue early on. The major uncertainty here is the stability of the fibrin matrix *in vivo*. Numerous animal studies have shown that the fibrin glue is still present at 4–6 weeks. Because postoperative fibrosis starts early, the flaps become stuck secondary to fibrosis even prior to full degradation of the glue (**Figures 8A to D**). The ensuing fibrosis acts like a firm scaffold around the haptic which prevents movement along the long axis (**Figure 9A**). To further make the IOL rock stable, the author has started tucking the haptic tip into the sclera wall through a tunnel. This prevents all movement of the haptic along the transverse axis as well (**Figure 9B**). The stability of the lens first comes through the tucking of the haptics in the scleral pocket created. The tissue glue then gives it extra stability and also seals the flap down. Externalization of the greater part of the haptics along its curvature stabilizes the axial positioning of the IOL and thereby prevents any IOL tilt.

Steps of Surgery for a Glued IOL

It is to look at the various steps of surgery for a glued IOL (**Figures 10 to 38**). This shows the way that an injectable foldable IOL can be glued into an eye with no capsules.



FIGURES 7A AND B: Anterior segment OCT showing the scleral flap placement on day 1 (A) and adhesion well maintained till six weeks (B)



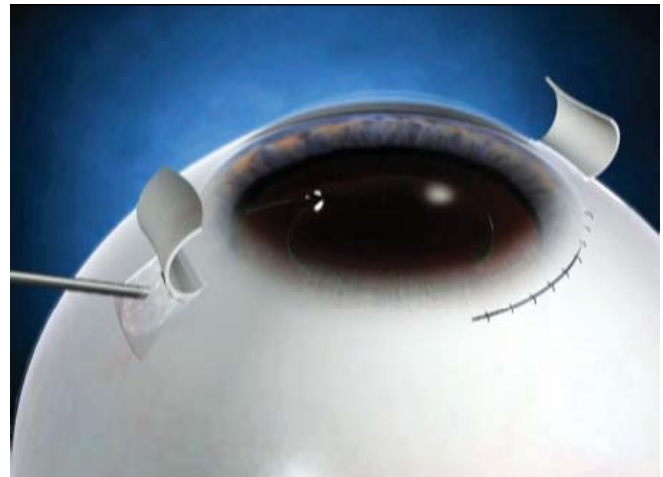
(A) IOL haptic grasped with a microsurgical technology MST forceps(USA)



(B) 26 gauge needle creates a scleral pocket at the edge of the flap

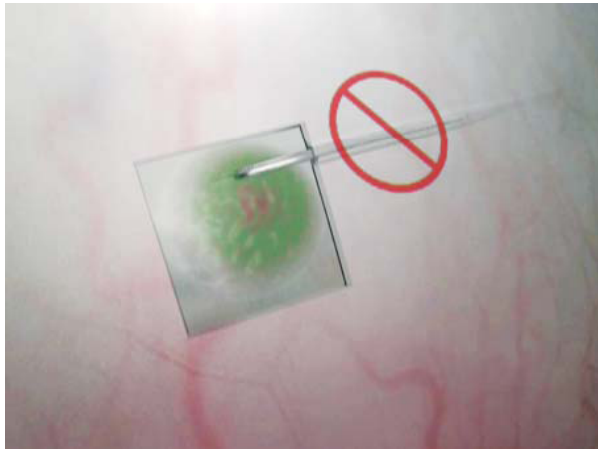

(C) IOL haptic tucked into the scleral pocket

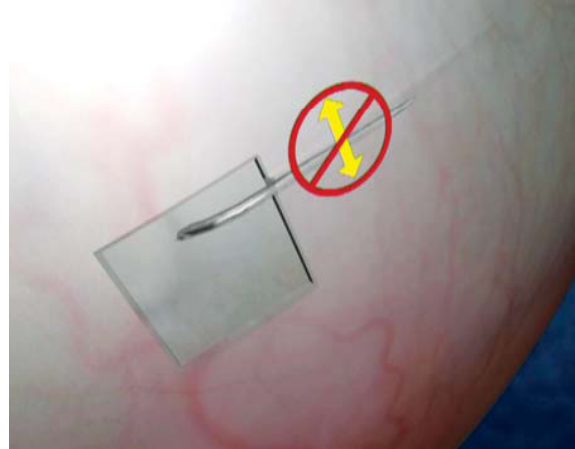

(D) Fibrin glue applied under the scleral flaps

FIGURES 8A TO D: Surgical technique of the glued IOL



(A) Long axis movement is prevented by the tissue glue



(B) Transverse axis movement is prevented by the scleral tuck

FIGURES 9A AND B: Stability of the IOL

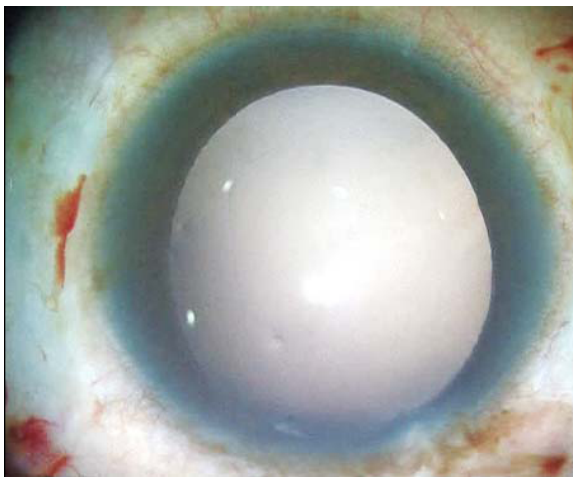


FIGURE 10: *Aphakic case. No capsule seen*

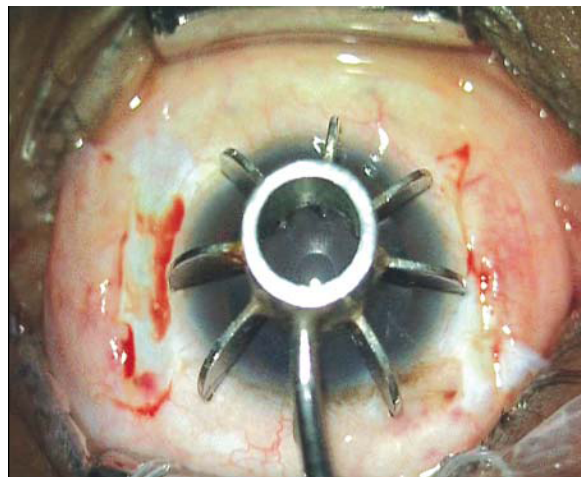


FIGURE 11: *Scleral markers applied on the cornea. This will help to get marks created on the cornea 180 degrees apart to make sclera flaps*

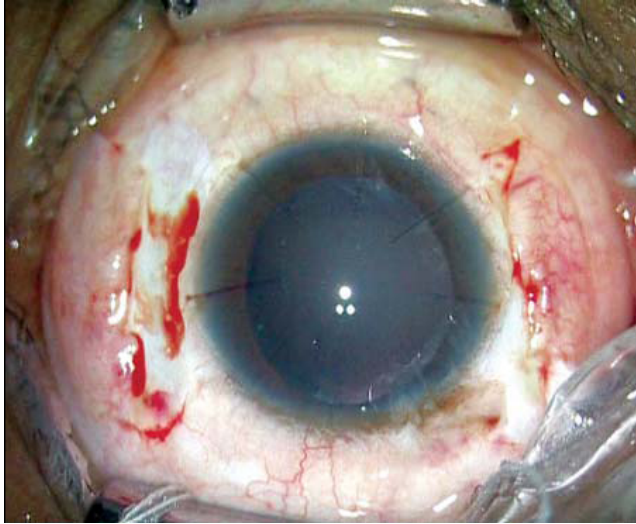


FIGURE 12: Marks made on the cornea. Conjunctiva cut on either side of the marks

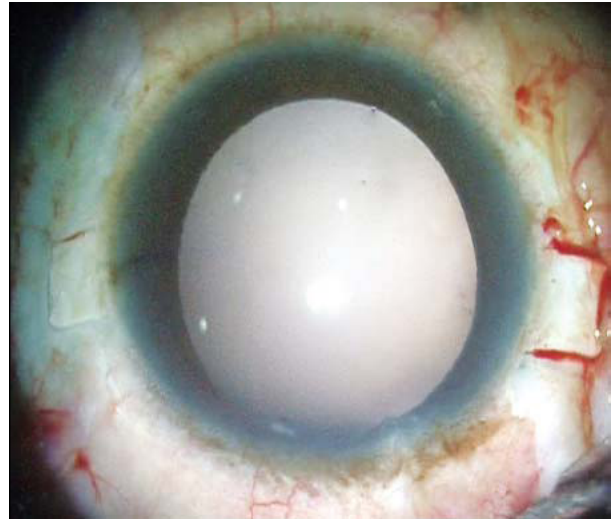


FIGURE 13: Scleral flaps made 180 degrees apart

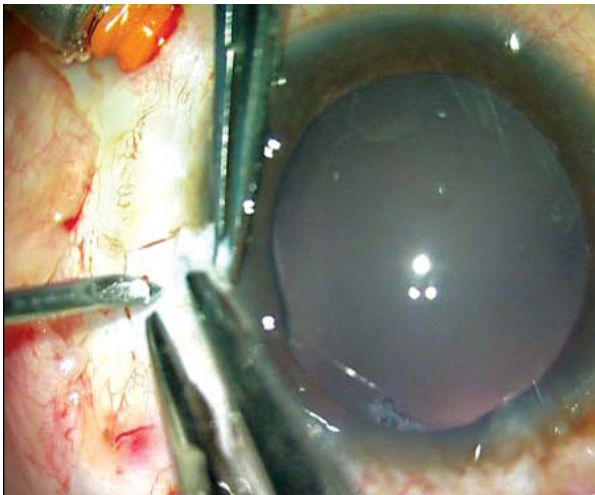


FIGURE 14: Sclerotomy made 1 mm from the limbus under the sclera flap using a 20 G needle

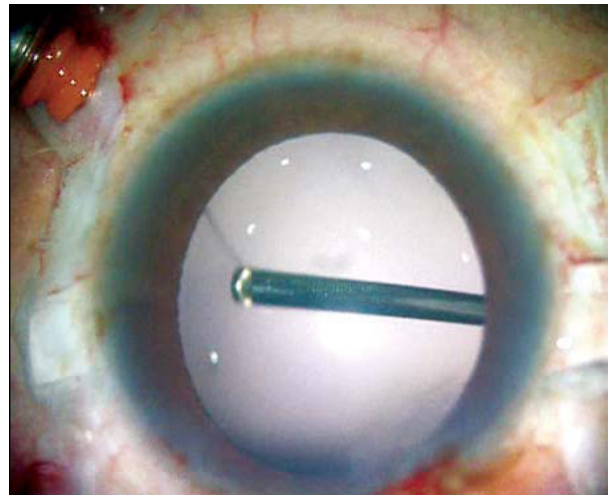


FIGURE 15: 23 G vitrectomy to remove anterior and midvitreous

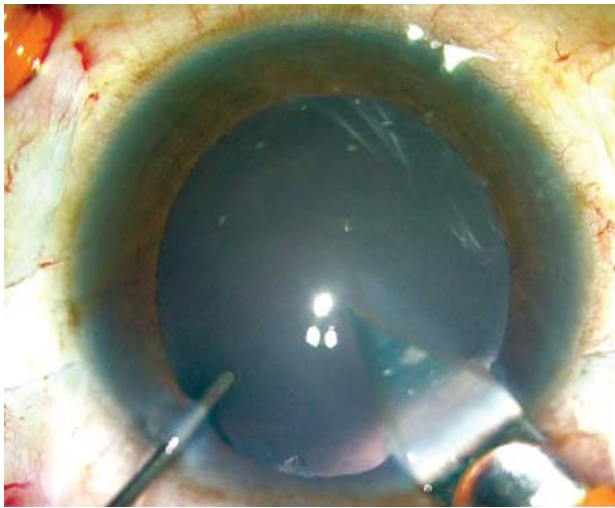


FIGURE 16: Clear corneal incision

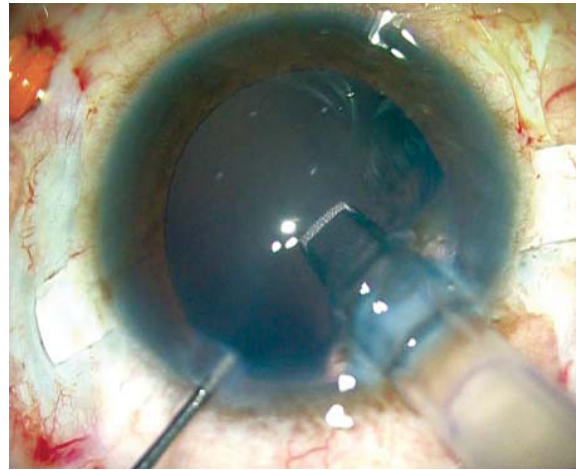


FIGURE 17: Foldable 3 piece IOL being injected slowly. It is to note the cartridge is inside the eye. One should not do wound assisted as the injection might happen too fast. This can either break the IOL or push it so fast that it might go into the vitreous cavity

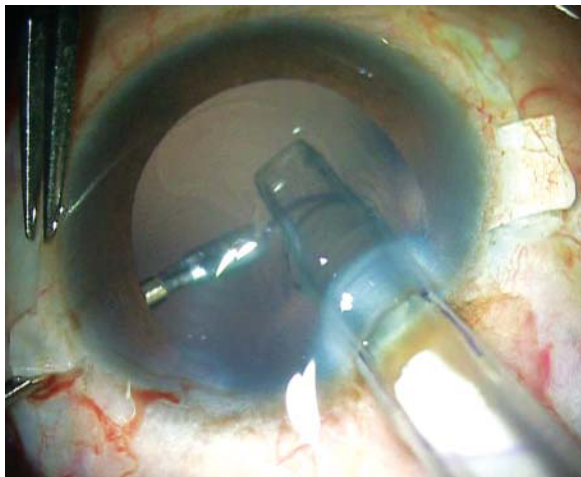


FIGURE 18: Foldable IOL injection continued with one hand. This injector has a pushing mechanism so one hand can be used. The other hand holds an end opening microrhexis forceps (23 G) and is passed

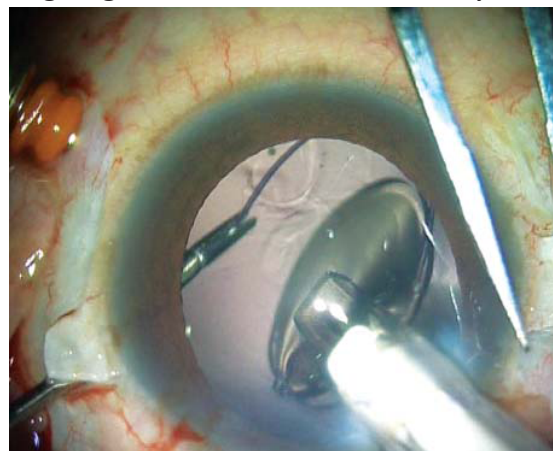


FIGURE 19: End opening forceps grabs the haptic tip

through the sclerotomy under the sclera flap and is ready to grab the haptic

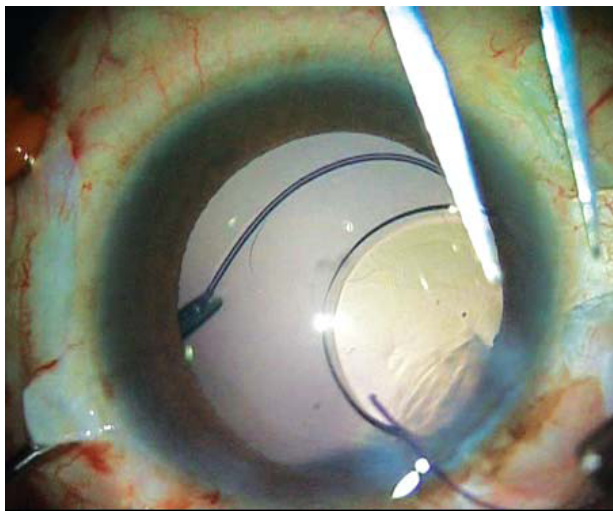


FIGURE 20: Forceps pulls the haptic while injection of the foldable IOL is continued

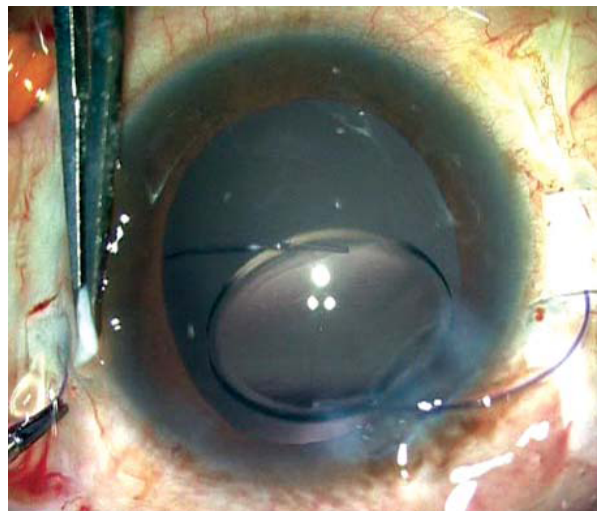


FIGURE 21: Haptic externalized

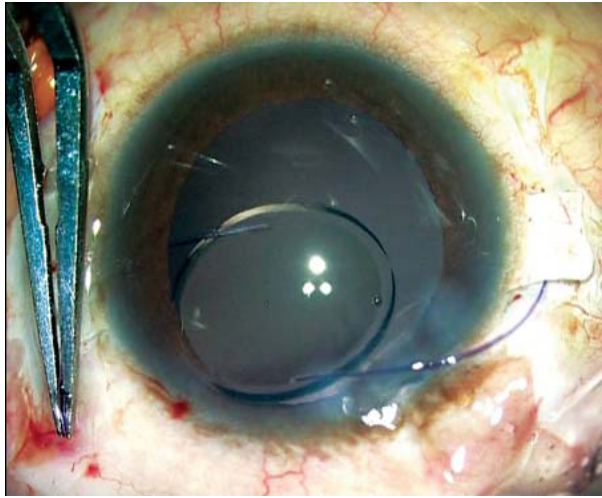


FIGURE 22: Assistant holds the haptic which is externalized

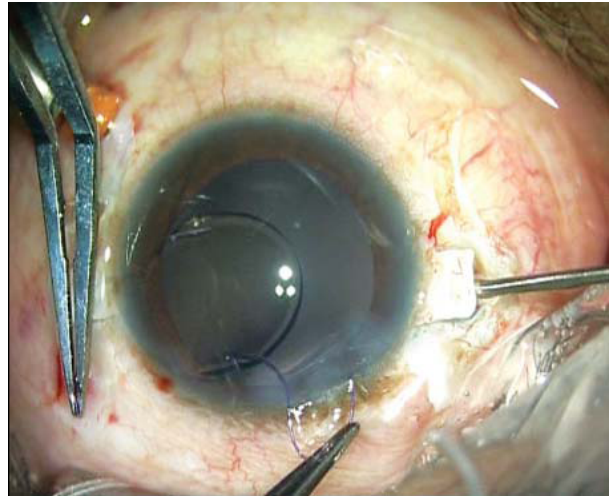


FIGURE 23: Trailing haptic is flexed into the anterior chamber. The other hand holds the end opening microhexis forceps and is passed through the other sclerotomy under the sclera flap

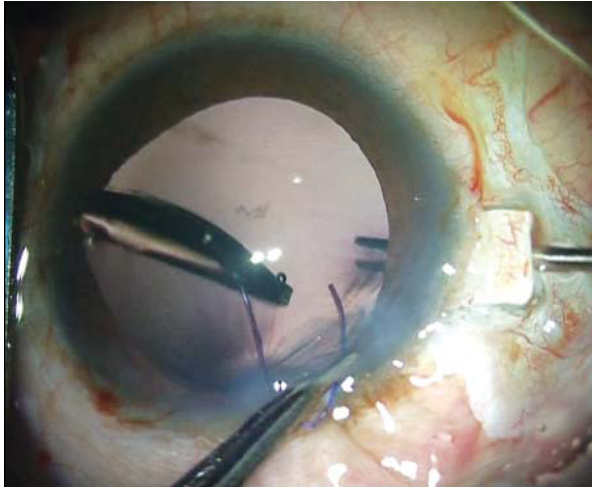


FIGURE 24: End opening forceps ready to grab the haptic tip

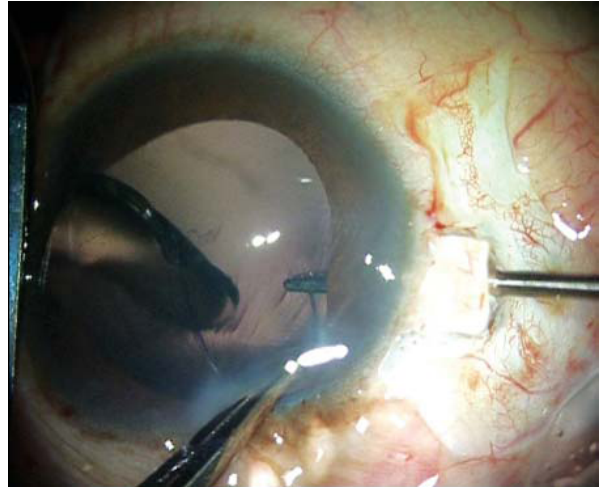


FIGURE 25: Haptic caught

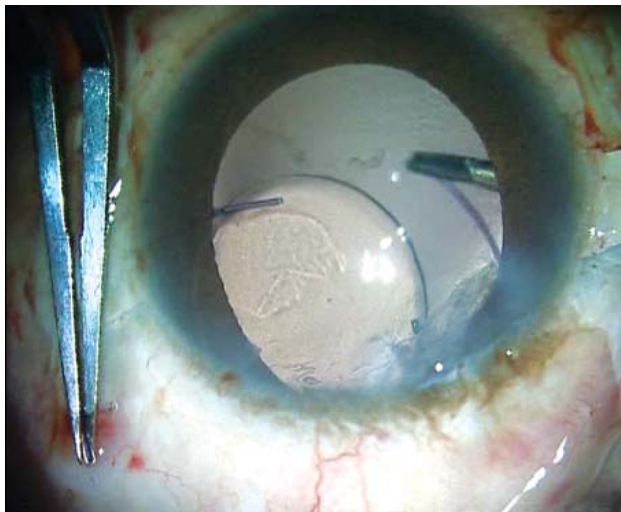


FIGURE 26: Haptic is gradually pulled towards the sclerotomy

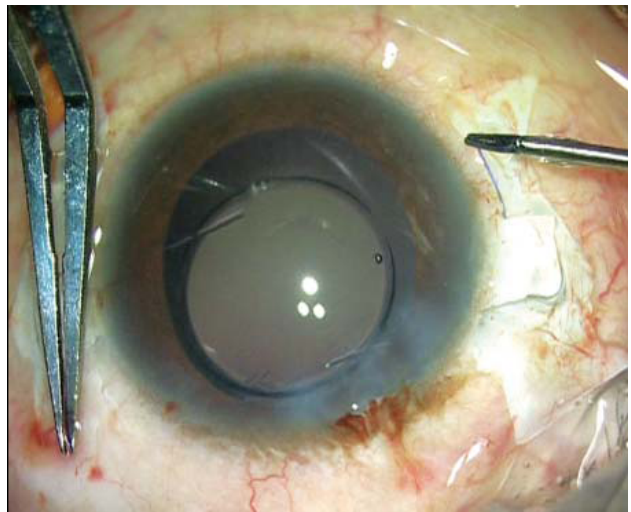


FIGURE 27: Haptic externalized

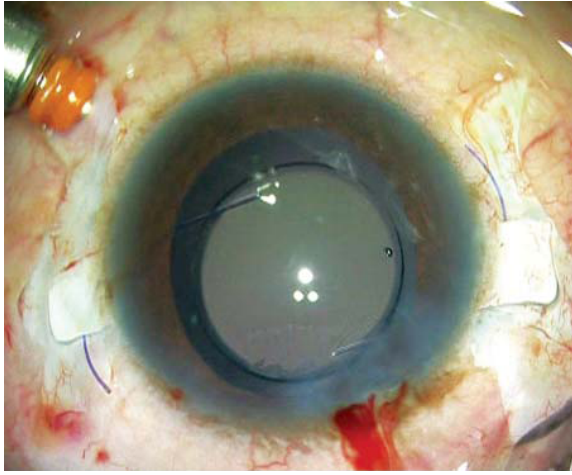


FIGURE 28: Both haptics externalized and can be seen lying under the sclera flaps

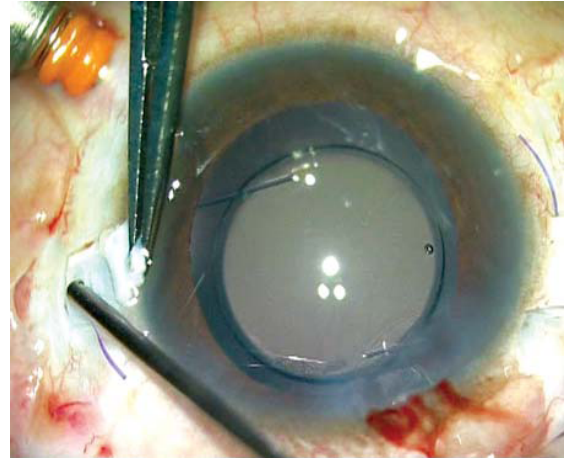


FIGURE 29: Vitrectomy done at the sclerotomy site

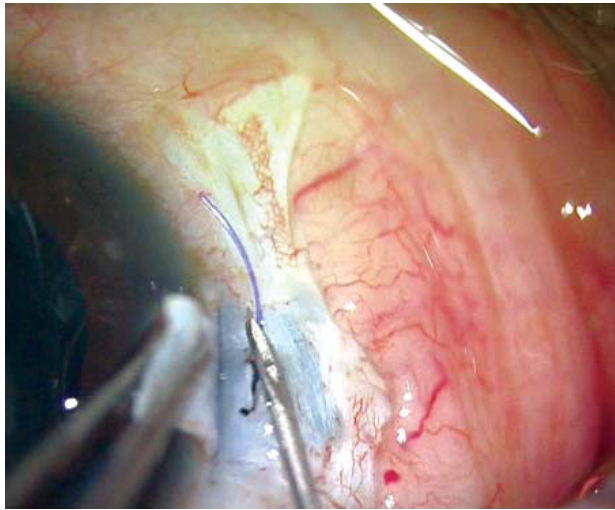


FIGURE 30: 26 G needle makes a sclera pocket at the edge of the flap where the haptic is seen

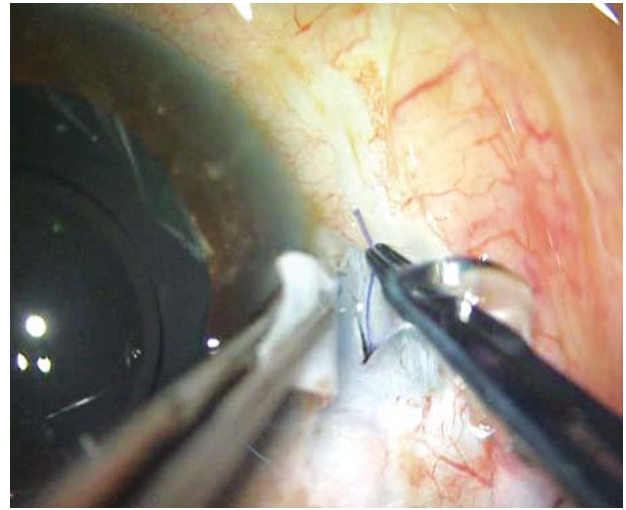


FIGURE 31: Forceps holds the haptic and flexes it to tuck it inside the scleral pocket

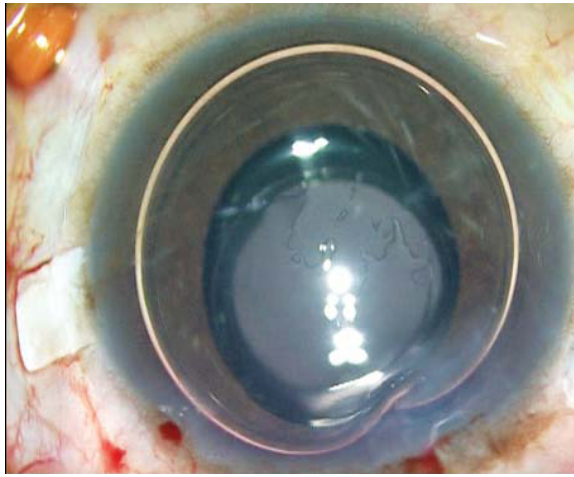


FIGURE 32: Haptic in the sclera pocket

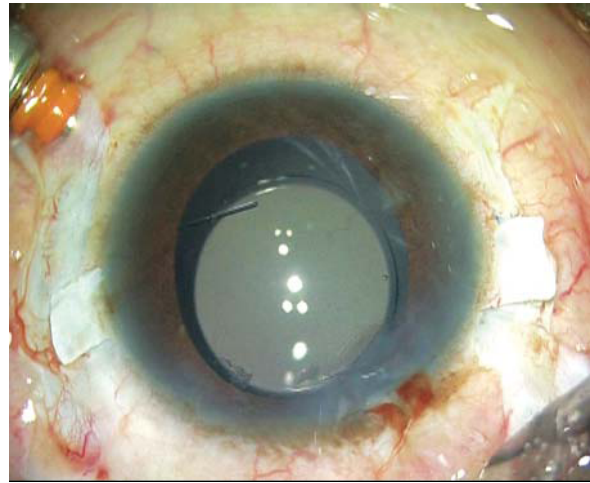


FIGURE 33: PC IOL stable

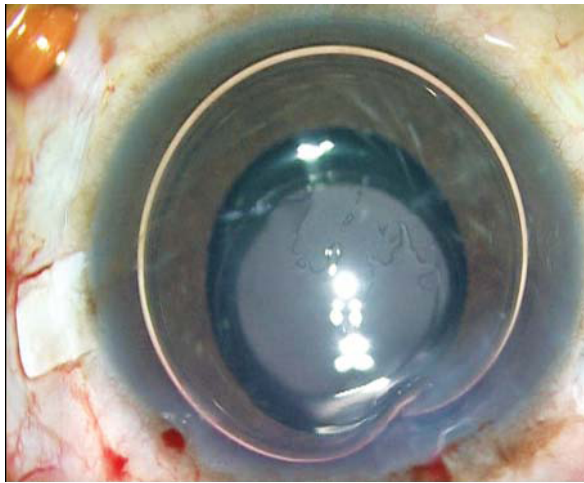


FIGURE 34: Infusion cut off and air fills the anterior chamber

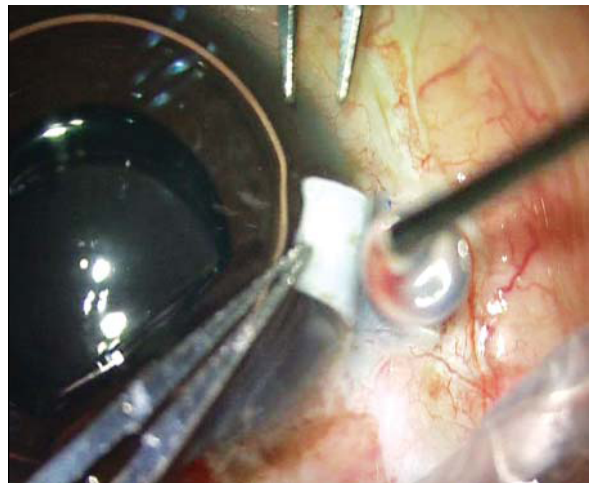

FIGURE 35: Fibrin glue (Tiessel, Baxter) application

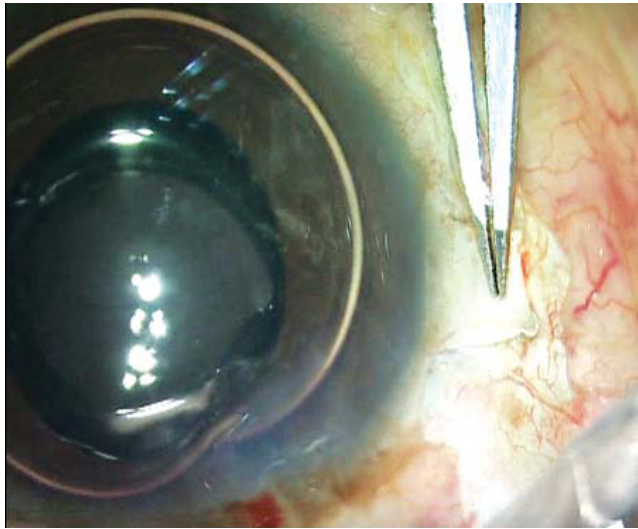


FIGURE 36: Scleral flap sealed

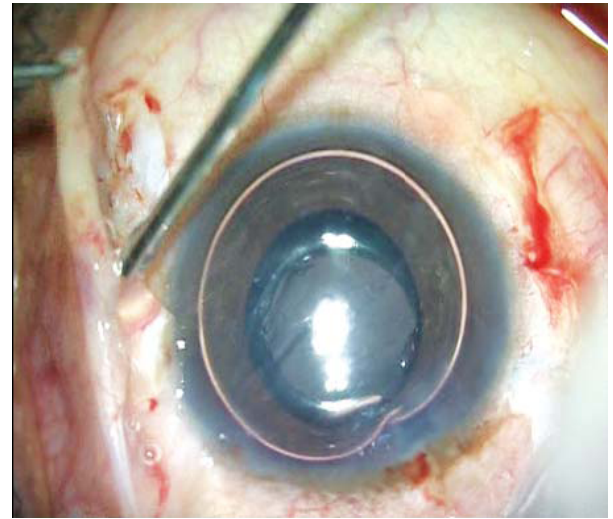


FIGURE 37: Fibrin glue applied on conjunctiva and clear corneal incision to seal them

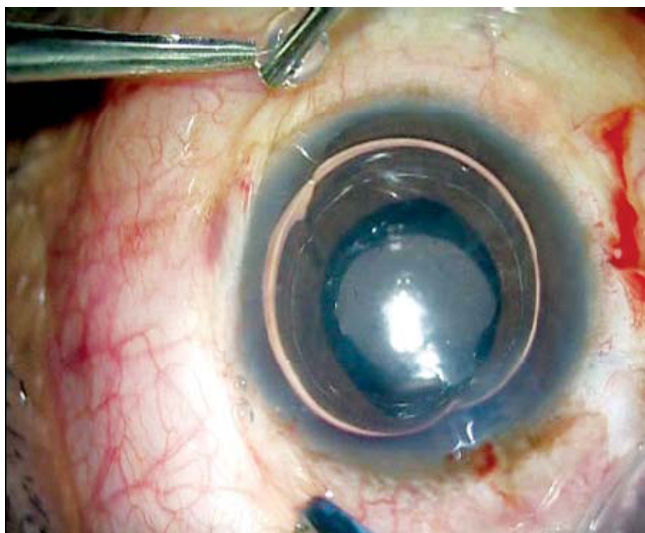


FIGURE 38: Immediate postoperation on table

REFERENCES

1. Vajpayee RB, Sharma N, Dada T, et al. Management of posterior capsule tears. *Surv Ophthalmol.* 2001;45:473-88.
2. Wu MC, Bhandari A. Managing the broken capsule. *Curr Opin Ophthalmol.* 2008 ;19:36-40.
3. Agarwal A, Kumar DA, Jacob S, et al. Fibrin glue-assisted sutureless posterior chamber intraocular lens implantation in eyes with deficient posterior capsules. *J Cataract Refract Surg.* 2008;34:1433–8.
4. Prakash G, Kumar DA, Jacob S, et al. Anterior segment optical coherence tomography-aided diagnosis and primary posterior chamber intraocular lens implantation with fibrin glue in traumatic phacocoele with scleral perforation. *J Cataract Refract Surg.* 2009;35:782-4.
5. Prakash G, Jacob S, Kumar DA, et al. Femtosecond assisted keratoplasty with fibrin glue-assisted sutureless posterior chamber lens implantation: a new triple procedure. *J Cataract Refract Surg.* In press (manuscript no 08-919).
6. Agarwal A, Kumar DA, Prakash G, et al. Fibrin glue–assisted sutureless posterior chamber intraocular lens implantation in eyes with deficient posterior capsules [Reply to letter]. *J Cataract Refract Surg.* 2009;35:795-6.
7. Nair V, Kumar DA, Prakash G, et al. Bilateral spontaneous in-the-bag anterior subluxation of PC IOL managed with glued IOL technique: A case report. *Eye Contact Lens.* 2009; 35(4):215-7.
8. Teichmann KD, Teichmann IAM. The torque and tilt gamble. *J Cataract Refract Surg.* 1997;23:413-8.
9. Jacobi KW, Jagger WS. Physical forces involved in pseudophacodonesis and iridodonesis. *Albrecht Von Graefes Arch Klin Exp Ophthalmol.* 1981;216:49-53.
10. Price MO, Price FW Jr, Werner L, et al. Late dislocation of scleral-sutured posterior chamber intraocular lenses. *J Cataract Refract Surg.* 2005 Jul;31(7):1320-6.

11. Solomon K, Gussler JR, Gussler C, et al. Incidence and management of complications of transsclerally sutured posterior chamber lenses. *J Cataract Refract Surg.* 1993;19:488-93.
12. Asadi R, Kheirkhah A. Long-term results of scleral fixation of posterior chamber intraocular lenses in children. *Ophthalmology.* 2008 Jan;115(1):67-72.
13. Lanzetta P, Menchini U, Virgili G, et al. Scleral fixated intraocular lenses: an angiographic study. *Retina.* 1998;18:515–20.